

# Effects of a comprehensive scar management to the face that includes transparent face orthosis: a case report.

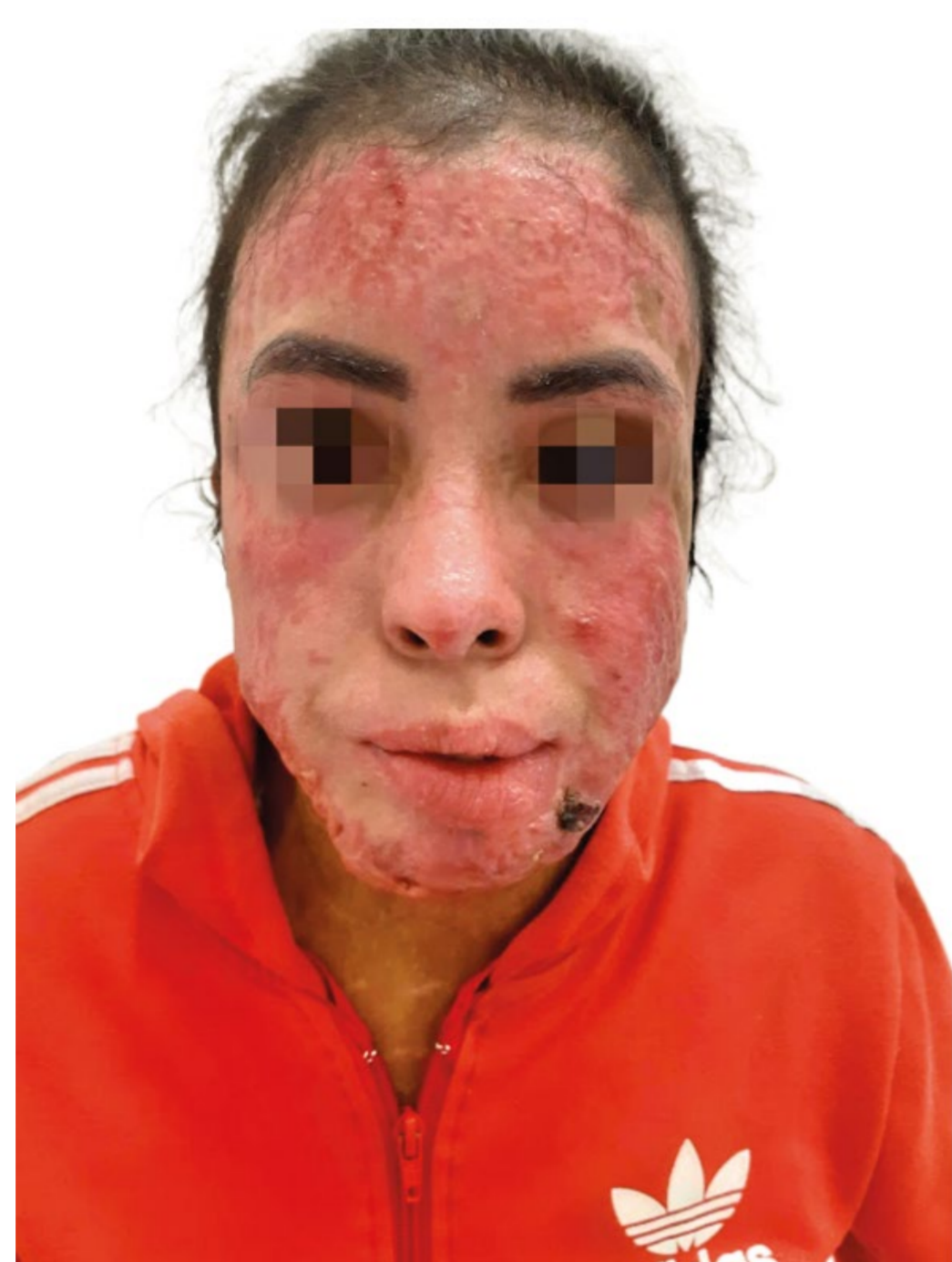**Authors:** Luz Ángela Calderón Calderón, OT\*/\*\*\* ; Lida Isabel Meneses Valencia, OT\*/\*\*\* ; Liliana Arango Gaviria, PT\*\*/\*\*\* ; Olga Lucía Medina Agudelo OT\*/\*\*\*

**Affiliation:** \*Occupational Therapist of the Burns Unit of San Vicente Fundación, Medellín, Colombia.

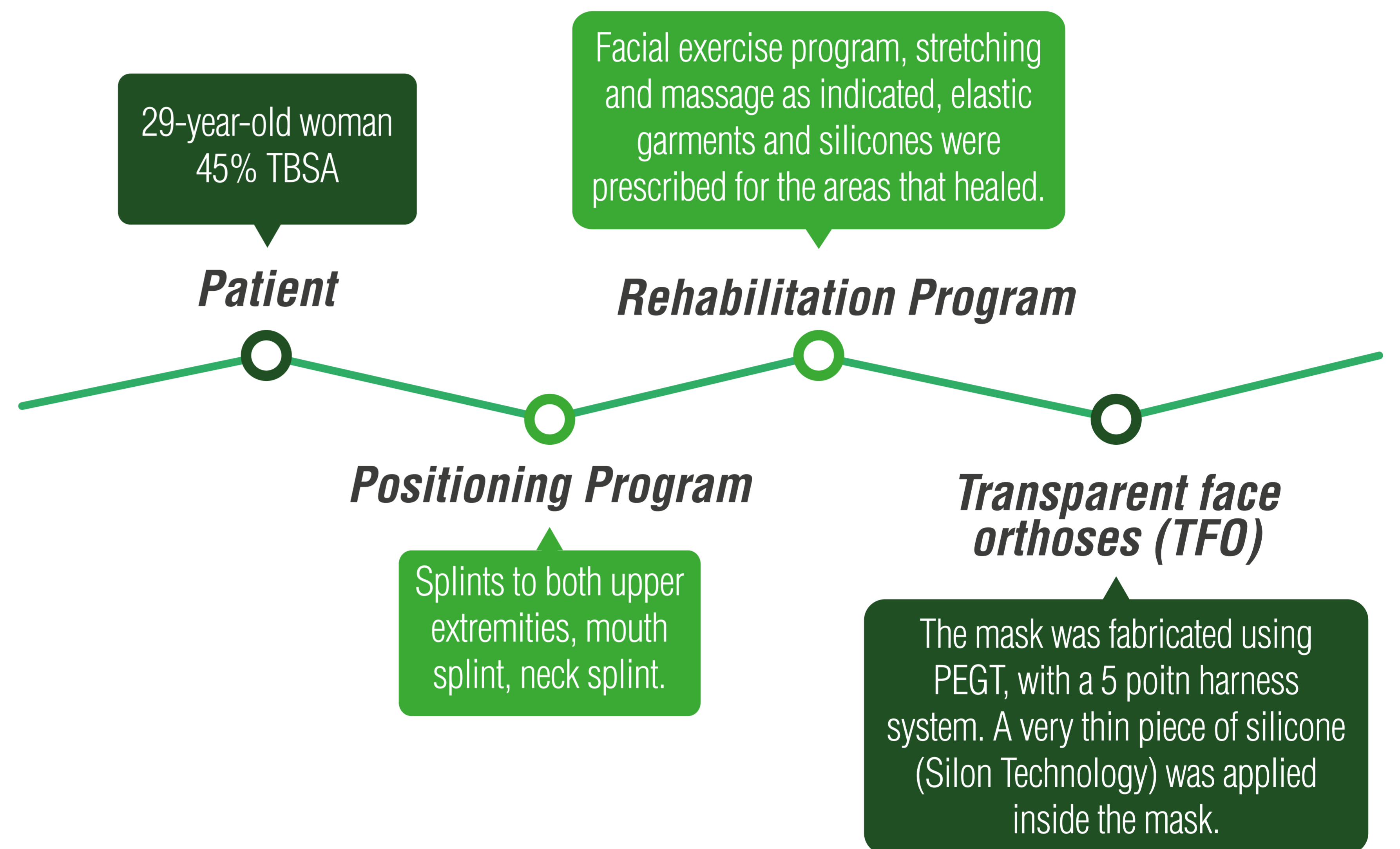
\*\*Physical Therapist of the Burns Unit of San Vicente Fundación, Medellín, Colombia. \*\*\*Therapists trained with Physicians For Peace.

## INTRODUCTION

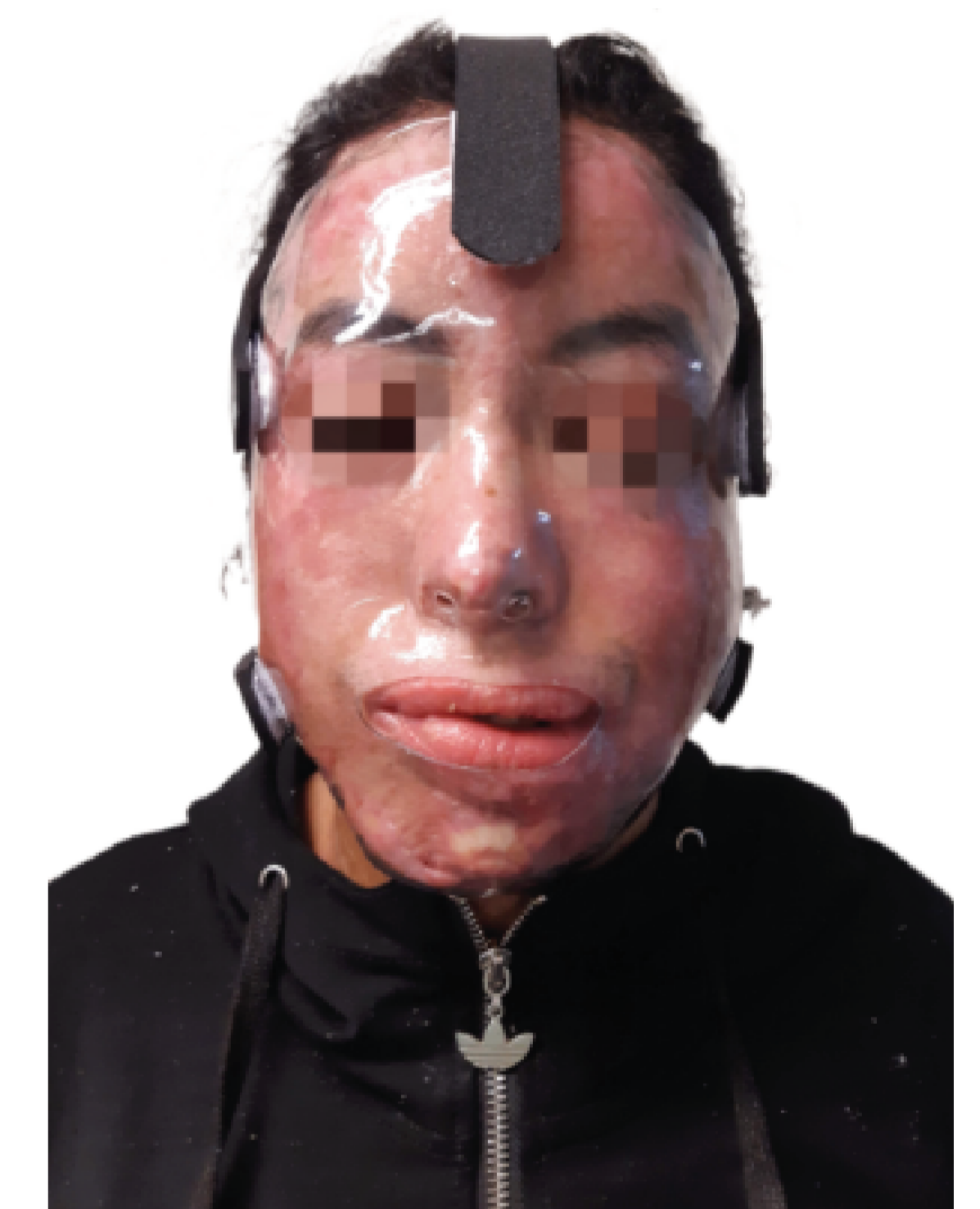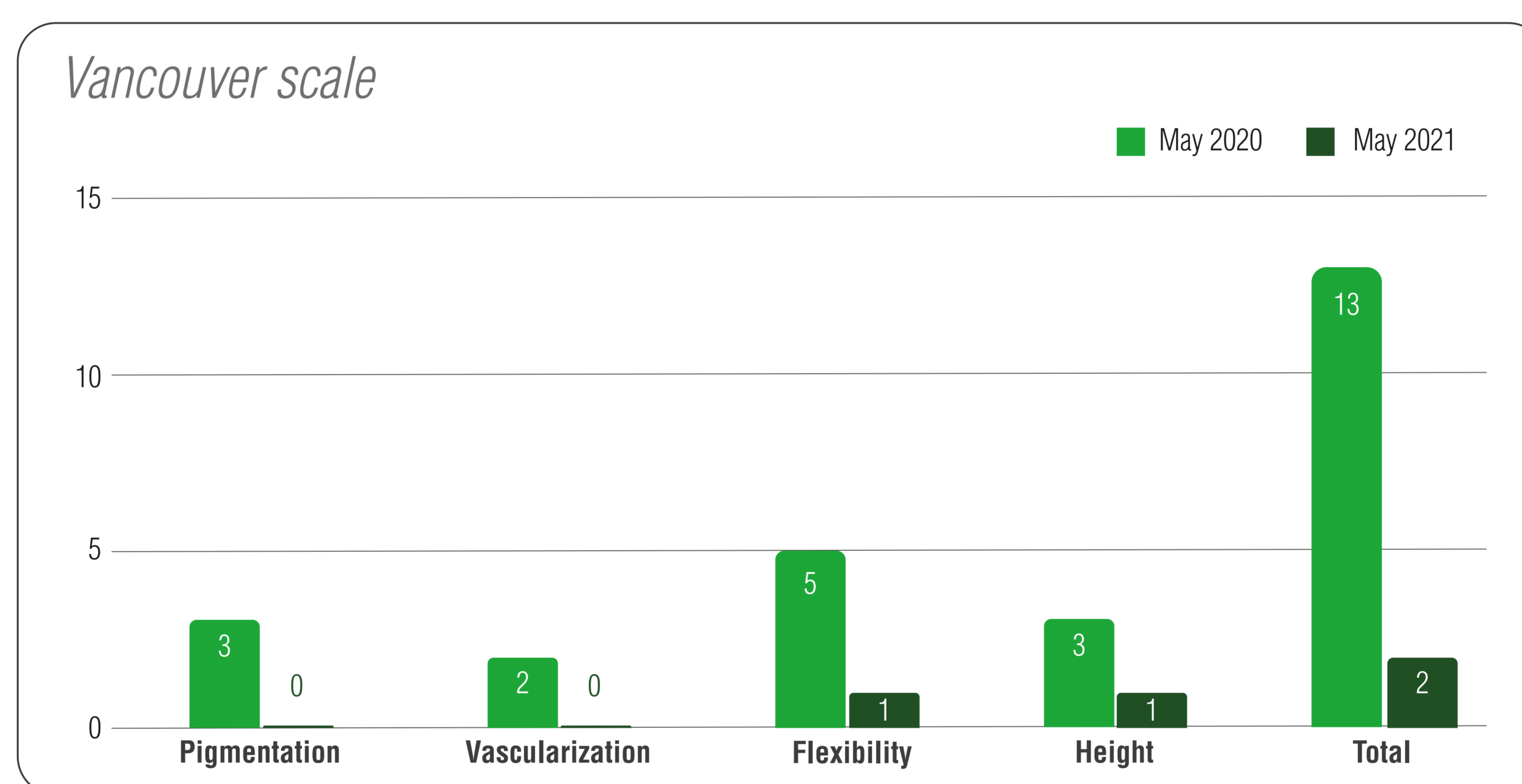
Patients, who sustained a deep partial or full thickness burns to the face, will almost certainly develop hypertrophic scars that can be functionally limiting and aesthetically can affect the patient's psychosocial wellbeing.



## METHODOLOGY



## RESULTS



May 2020

October 2020

December 2020

May 2021

## CONCLUSIONS

We believe that early and comprehensive management of scars on the face is the key to obtaining good functional and aesthetic results, contributing significantly to the psychosocial well-being of the patient and their social and professional reintegration.

The abstract can be downloaded using this QR code.



PHYSICIANS  
FOR PEACE



HOSPITAL  
SAN VICENTE  
FUNDACIÓN